























## 3 Wirbelsäule

3.1	Wirbelsäule sagittal .....	404
3.2	Halswirbelsäule sagittal .....	406
3.3	Halswirbelsäule coronar .....	412
3.4	Halswirbelsäule axial .....	418
3.5	Brustwirbelsäule sagittal .....	428
3.6	Brustwirbelsäule axial .....	434
3.7	Lendenwirbelsäule sagittal .....	436
3.8	Lendenwirbelsäule coronar .....	444
3.9	Lendenwirbelsäule axial .....	450
3.10	Wirbelsäule Sakrum .....	456

	Arterien
	Nerven
	Venen
	Knochen
	Fettgewebe
	Knorpel
	Sehne
	Diskus, Bandscheibe
	Flüssigkeit, Liquor
	Lymphknoten
	Ösophagus
	Leber, Drüsen
	Luft
	<b>M. erector spinae (lateral Trakt):</b> M. iliocostalis M. longissimus M. splenius Mm. intertransversarii Mm. levatores costarum
	<b>M. erector spinae (medialer Trakt):</b> <u>spinales System:</u> Mm. interspinales, M. spinalis <u>transversospinales System:</u> Mm. rotatores breves et longi M. multifidus M. semispinalis
	M. peroneus
	<b>kurze Nacken- und Kopfelenkmuskeln:</b> M. rectus capitis posterior major et minor M. obliquus capitis superior et inferior
	<b>prävertebrale Halsmuskulatur:</b> M. longus capitis et colli M. rectus capitis lateralis et anterior
	<b>Thoraxwandmuskulatur:</b> Mm. intercostales M. transversus thoracis Mm. subcostales Mm. scaleni

	<b>Rumpf-Schultergürtel-Arm-Muskulatur:</b> M. rhomboideus major et minor M. sternocleidomastoideus M. levator scapulae M. serratus anterior M. pectoralis minor M. trapezius M. latissimus dorsi
	<b>Rumpf-Bein-Bauch-Muskeln:</b> M. psoas M. quadratus lumborum M. piriformis M. gluteus medius
	<b>Gesichtsmuskulatur, ventrale Halsmuskulatur:</b> M. digastricus M. stylohyoideus M. sternohyoideus


cranial  
anterior  dorsal  
caudal

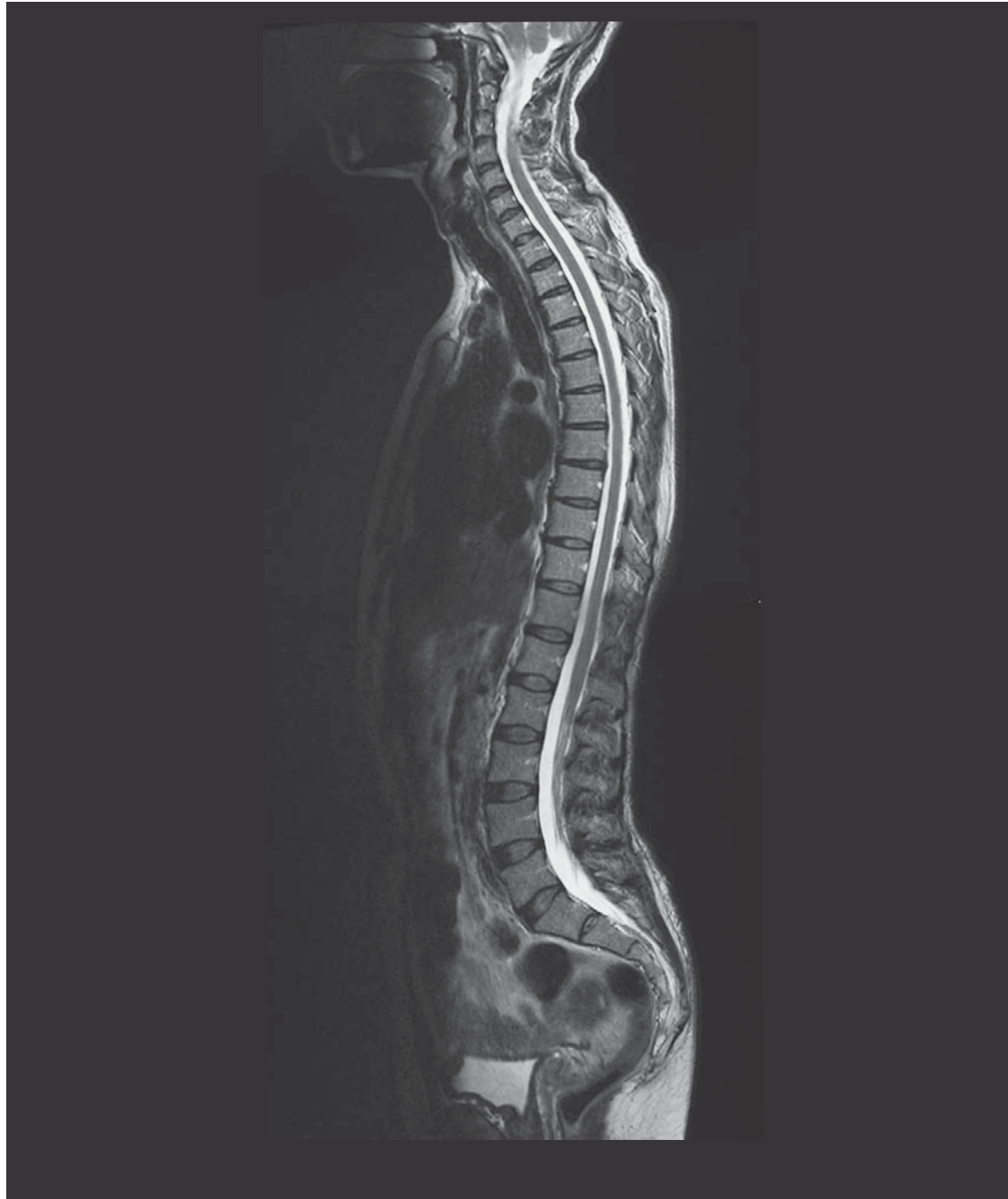

Abb. 3.1a

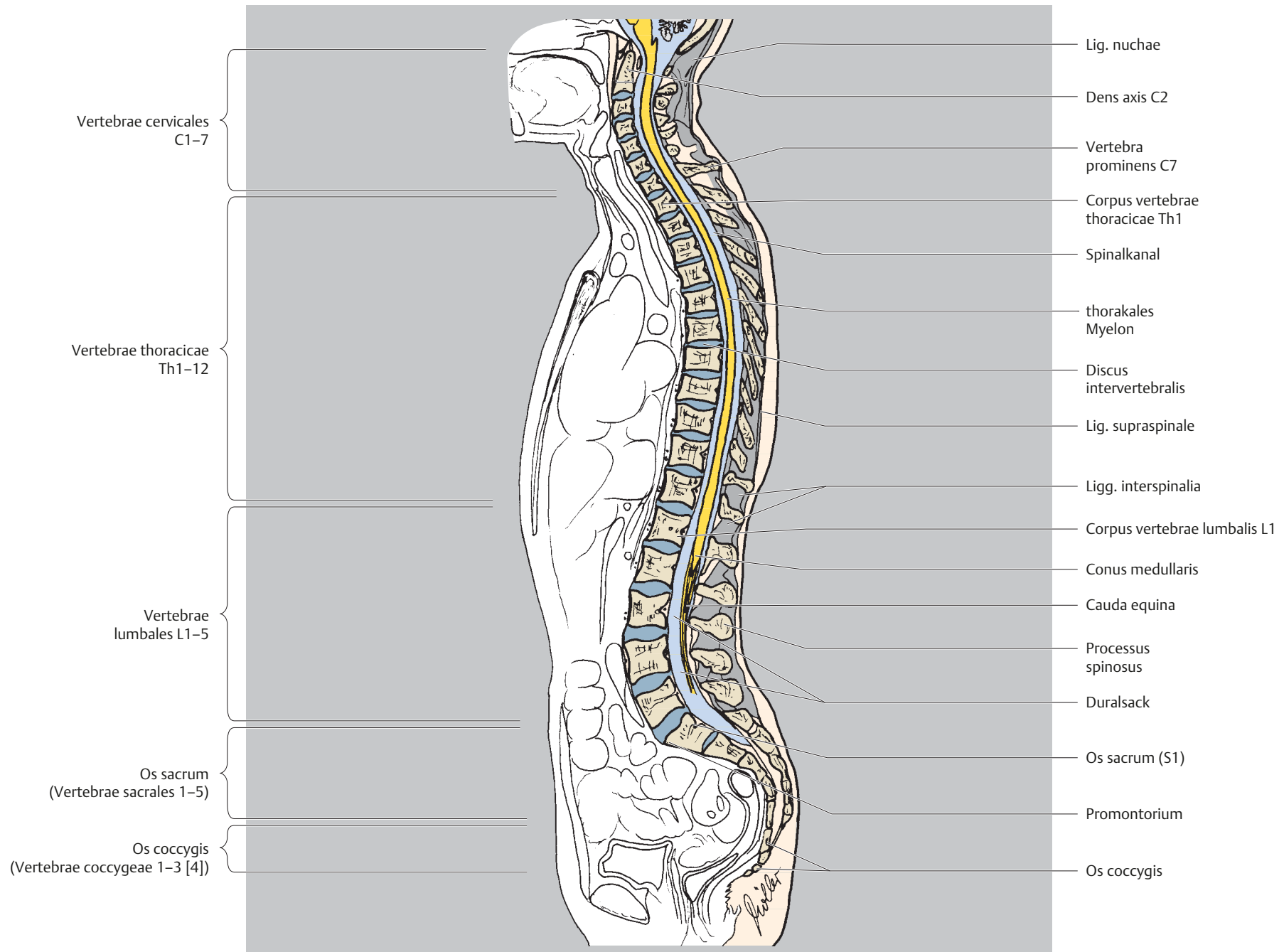
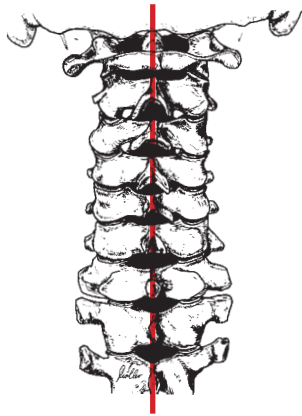


Abb. 3.1 b




cranial  
ventral  dorsal  
caudal

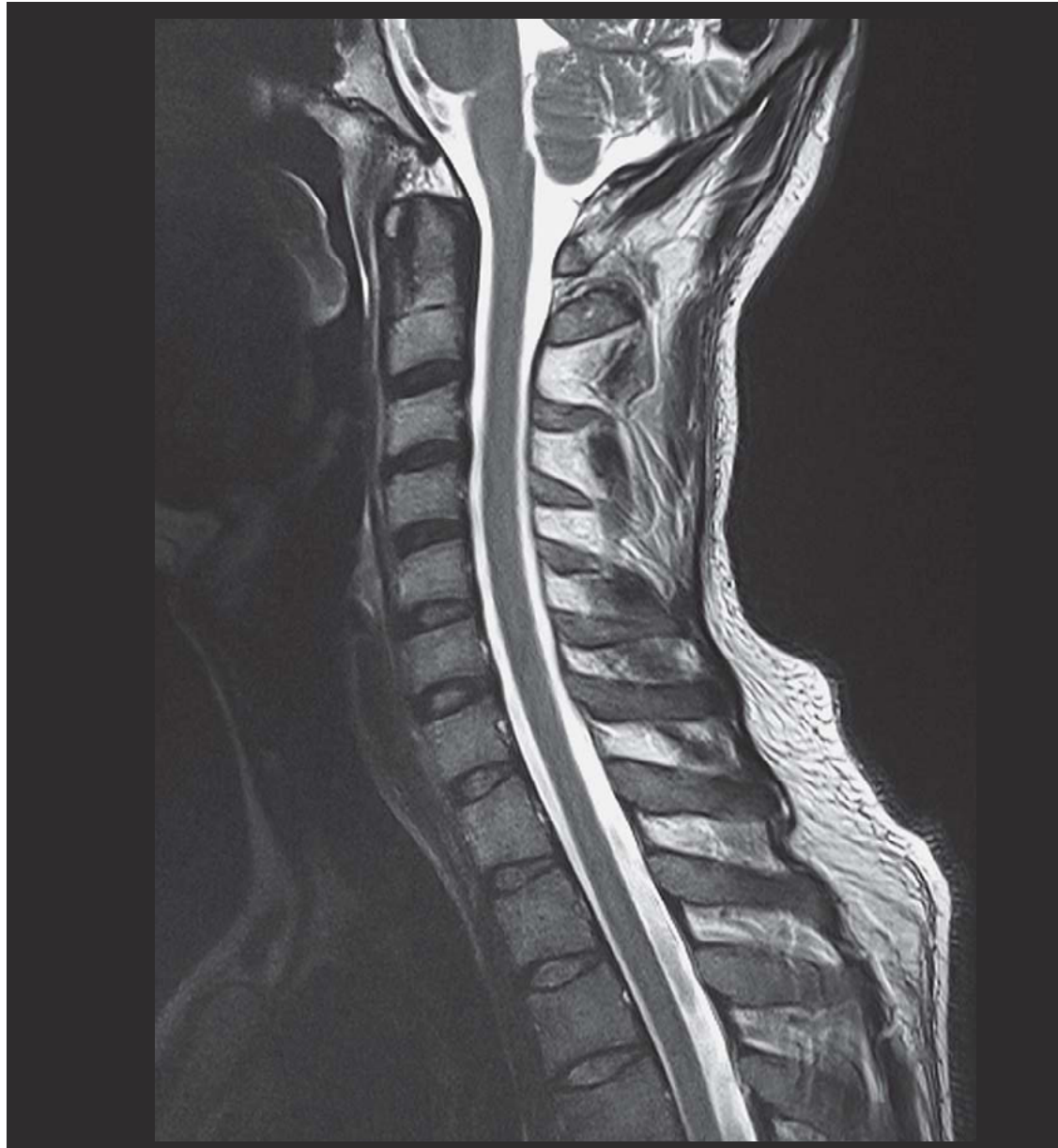

Abb. 3.2a

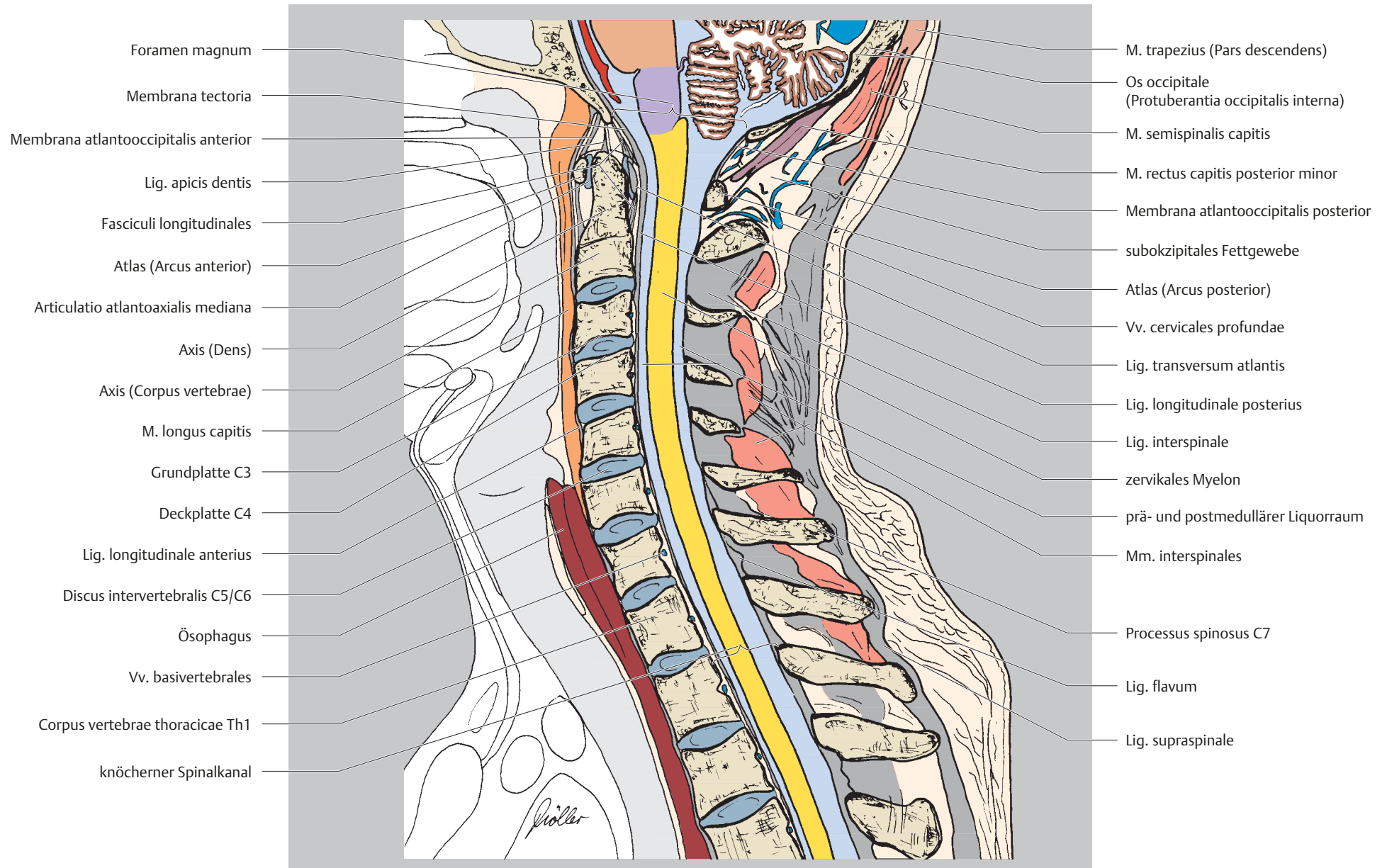
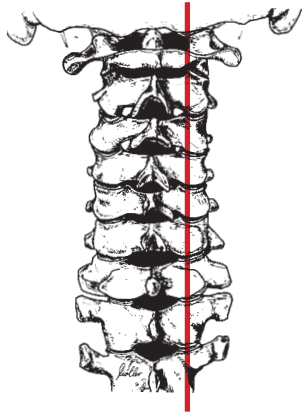


Abb. 3.2b




cranial  
ventral  dorsal  
caudal

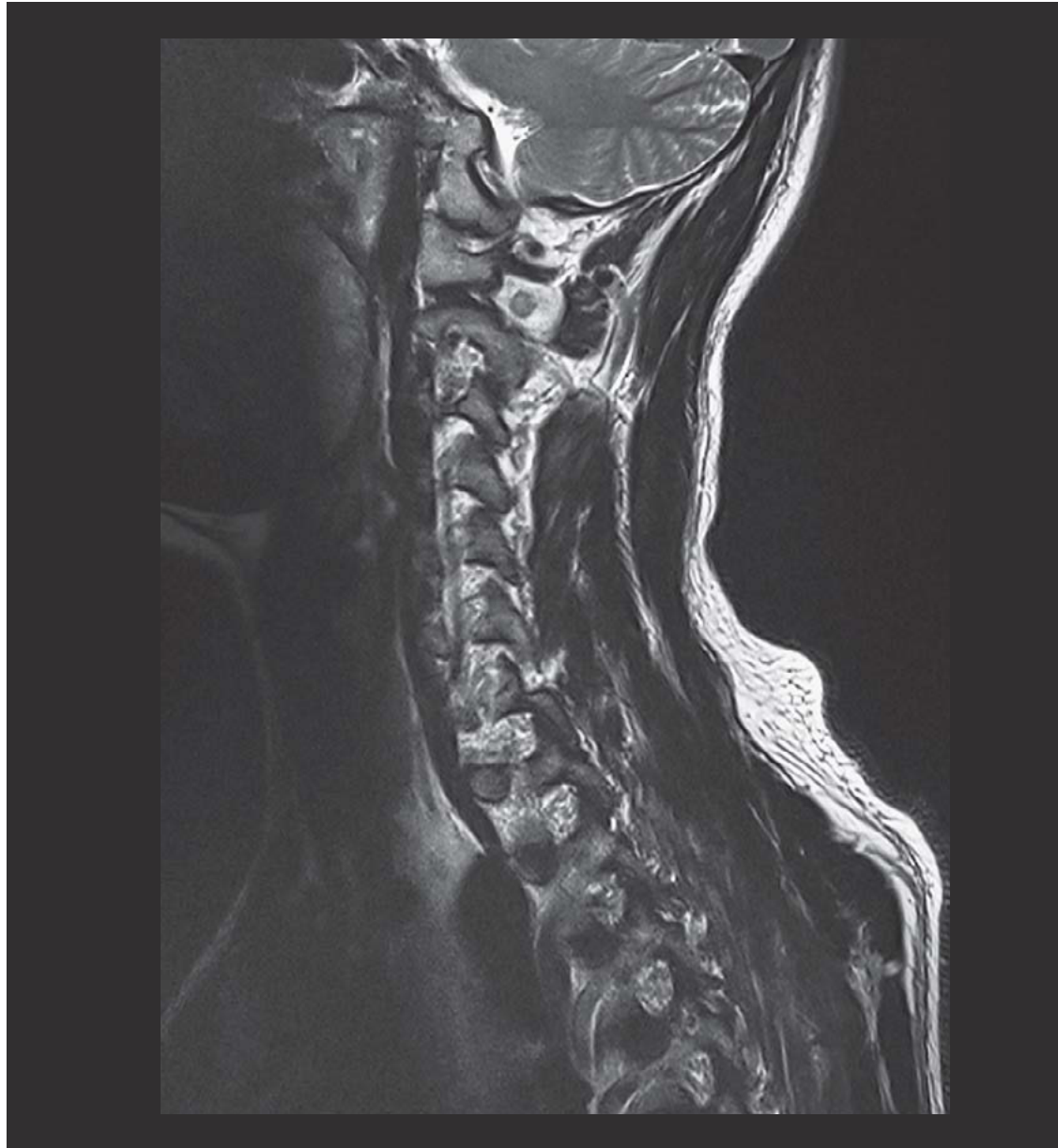

Abb. 3.3a

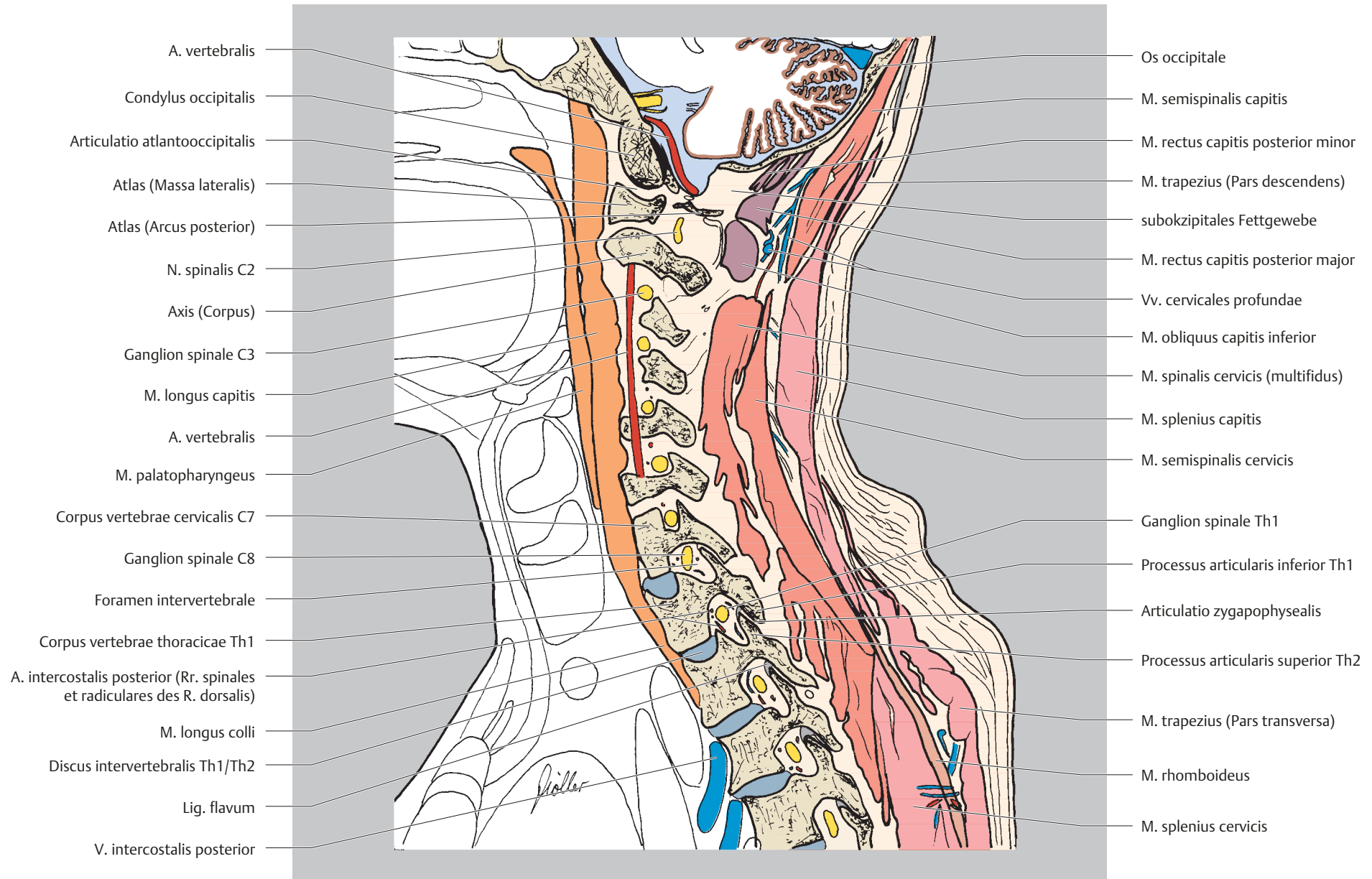
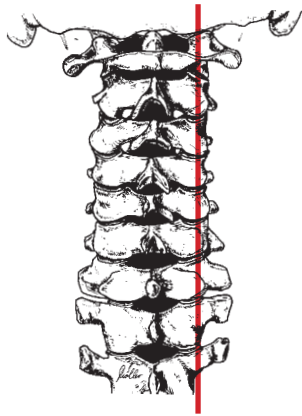


Abb. 3.3b




cranial  
ventral  dorsal  
caudal

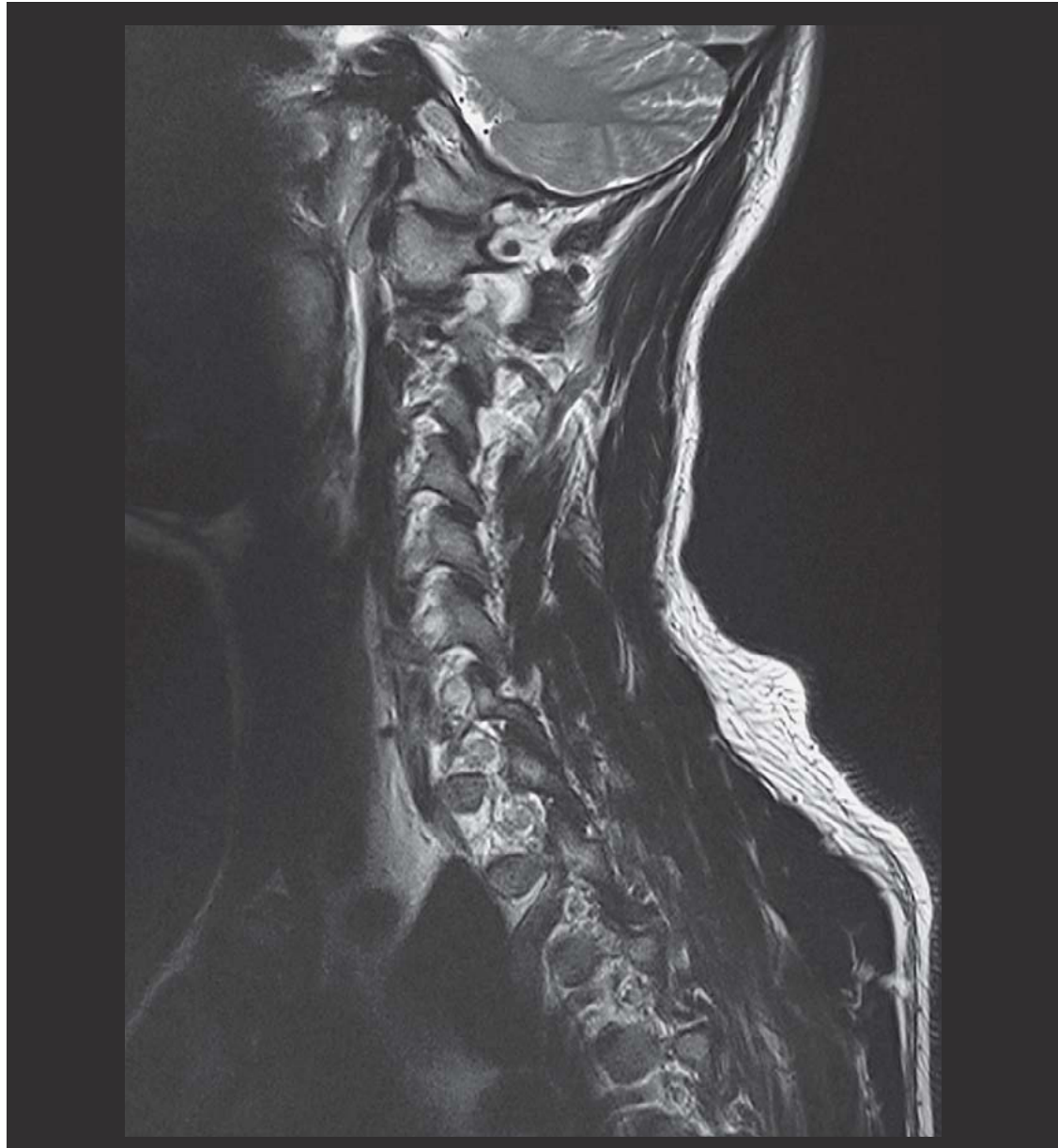

Abb. 3.4a

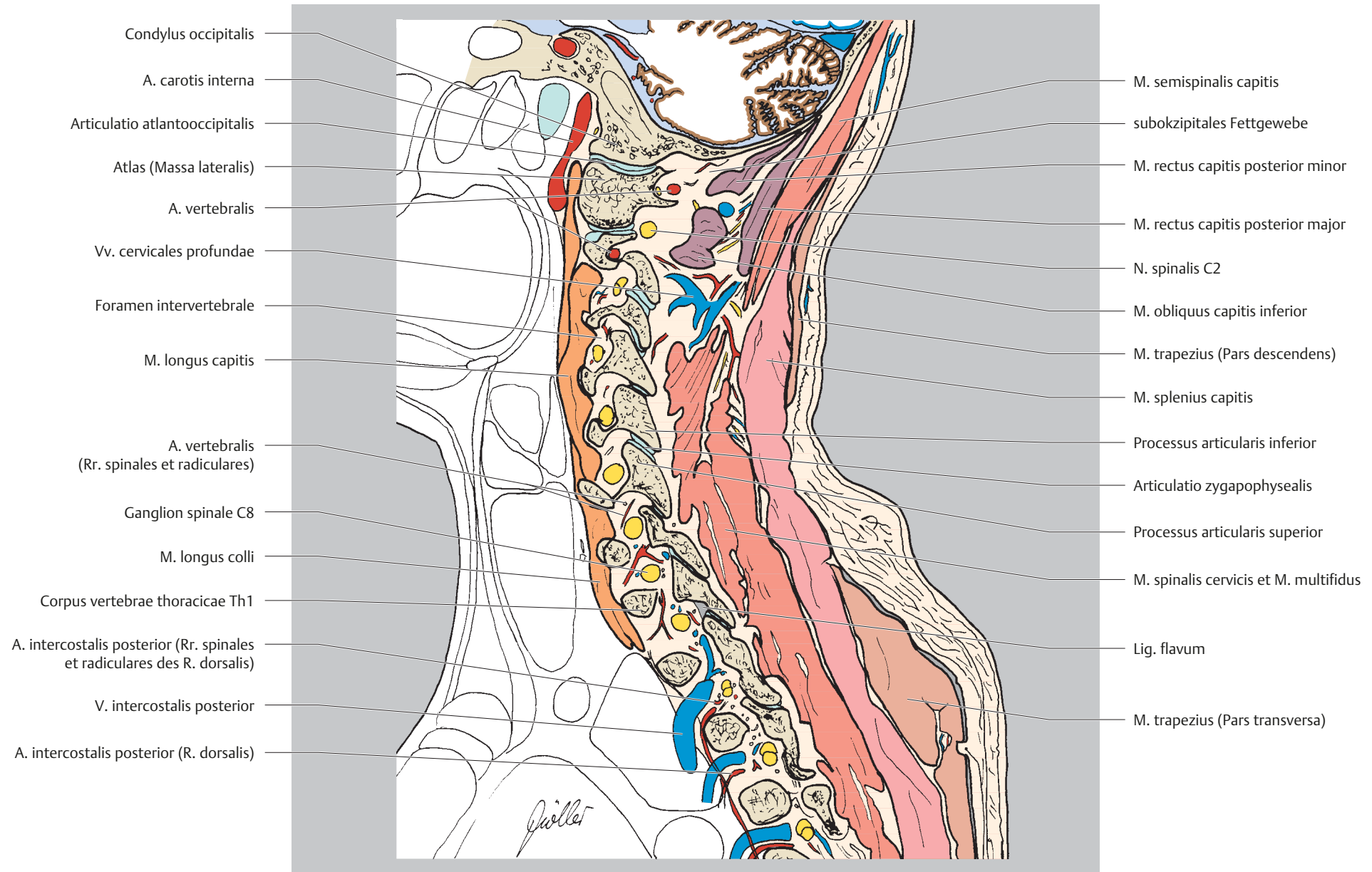
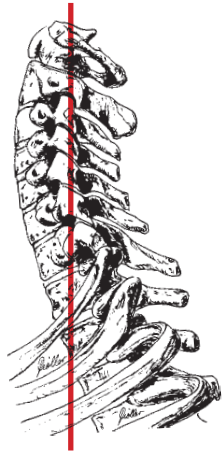


Abb. 3.4b




cranial  
rechts  links  
caudal

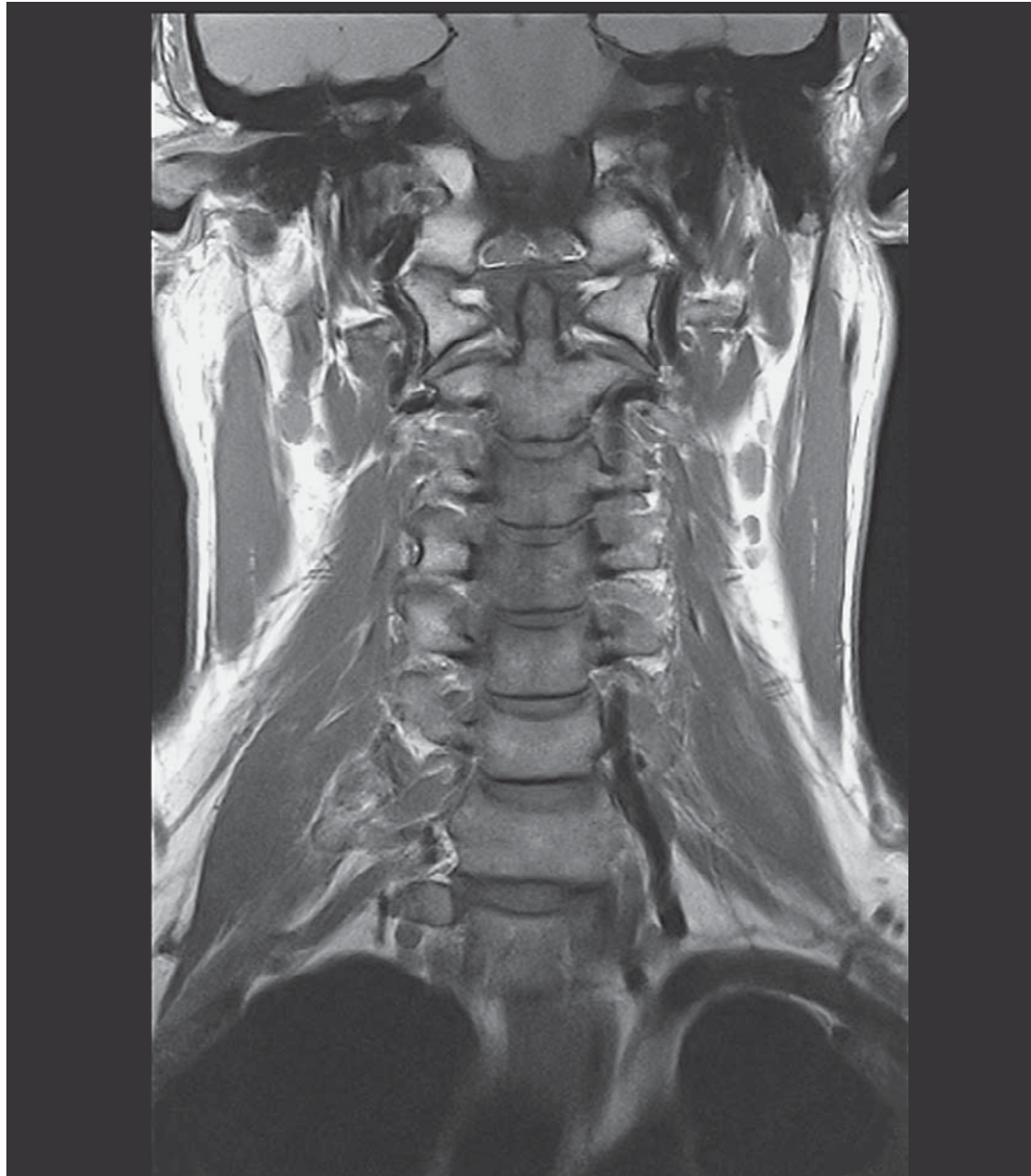

Abb. 3.5a